

## Case Report

# A rare post-COVID neurological complication: Case report of peripheral axonal sensory neuropathy

Raghavi Abhilesh Bembe<sup>1</sup>, Ram Babu<sup>1</sup>

<sup>1</sup>Department of General Medicine, Jaipur Golden Hospital, New Delhi, India.



**\*Corresponding author:**

Raghavi Abhilesh Bembe,  
Department of General  
Medicine, Jaipur Golden  
Hospital, New Delhi, India.

[bembeyraghavi@gmail.com](mailto:bembeyraghavi@gmail.com)

Received: 21 November 2022  
Accepted: 03 March 2023  
Epub Ahead of Print: 07 April 2023  
Published: 27 June 2023

**DOI**

10.25259/AUJMSR\_81\_2022

**Quick Response Code:**



## ABSTRACT

The present outbreak of Severe Acute Respiratory Syndrome CoronaVirus-2 (SARS-CoV-2), a “novel coronavirus” with neurotropic potential, has presented with multiple cases of neurological manifestations also. SARS-CoV-2 infection is found to be associated with an increased incidence of diverse neurological manifestations such as hyposmia/anosmia, encephalopathy and encephalomyelitis, ischemic stroke and intracerebral hemorrhage, and neuromuscular diseases involving both central and peripheral nervous system. People with these severe complications were most likely elderly with medical comorbidities, especially hypertension and other vascular risk factors. However, in our case a 35-year-old young healthy man developed severe post-COVID neuropathy debilitating his daily activity further requiring rehospitalization. Our patient had developed severe SARS-CoV-2 pneumonia, with a computed tomography severity score of 18/25, needing non-invasive ventilation support, and intensive care unit care for a week, thereafter recovering well without complications and being discharged on room air. He had to be readmitted after 3 days in view of severe bilateral leg pain, being described as “pain crisis.” He was evaluated, a neurologist was involved in the case, with nerve conduction velocity (NCV) lower limbs revealing an axonal sensory neuropathy, which was treated with corticosteroid pulse therapy, gabapentin, and vitamin supplementation to which the patient responded well. Our case presented with pure sensory neuropathy post-COVID which is a rare presentation. The previous reports of treatment of SARS-CoV-2-associated neuropathy have also included corticosteroids and IVIG usually. Our patient improved with pulse therapy of corticosteroid and gabapentin. Thus, awareness and early treatment of peripheral neuropathy after SARS-CoV-2 is needed for good clinical outcomes.

**Keywords:** SARS CoV-2, Severe, Pneumonia, Post covid sequel, Neuropathy, Corticosteroids

## INTRODUCTION

The first reported case of a Severe Acute Respiratory Syndrome CoronaVirus-2 (SARS-CoV-2) infection (Wuhan, Hubei Province, China), in December 2019, began the outbreak of a novel coronavirus disease (COVID-19), and became a huge global health concern. On 30 January 2020, COVID-19 was registered as the sixth Public Health Emergency of International Concern by the World Health Organization, which was officially declared as a pandemic on March 11, 2020.<sup>[1]</sup>

The respiratory system is the most commonly affected, with symptoms including fever, cough and shortness of breath being the most commonly reported features. Observational studies have also suggested that COVID-19 may have neurologic manifestations, including headache, nausea, vomiting, myalgia, dizziness, hyposmia/anosmia, encephalitis, and impaired sensorium (encephalopathy).<sup>[2]</sup> Although the exact mechanism by which SARS-CoV-2 enters the central nervous system has not been determined yet, it may spread directly along the nerve roots

This is an open-access article distributed under the terms of the Creative Commons Attribution-Non Commercial-Share Alike 4.0 License, which allows others to remix, transform, and build upon the work non-commercially, as long as the author is credited and the new creations are licensed under the identical terms.

©2023 Published by Scientific Scholar on behalf of Adesh University Journal of Medical Sciences & Research

through cribriform plate or through the blood circulation, or cause damage through mechanisms that include free radical or immune-mediated injury.<sup>[3]</sup>

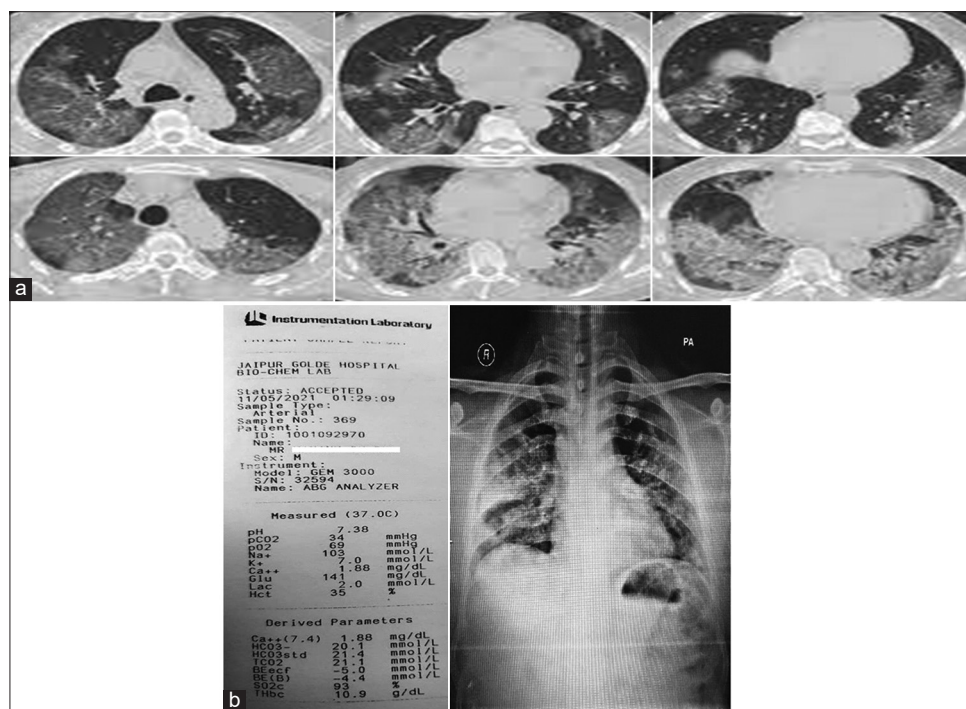
Neurological manifestations occur in about 36.4% of patients infected with SARS-CoV-2 and span several domains within the central and peripheral nervous system (PNS).<sup>[4]</sup> Subacute peripheral neuropathy has been rarely reported. Post-COVID neuropathy leads to various neurological symptoms and can cause significant morbidity, negatively affecting the quality of life of the patient. Thus, awareness about peripheral neuropathy as a sequel of SARS-CoV-2 is needed as early diagnosis helps in improved clinical outcome with proper treatment.

## CASE REPORT

A 35-year-old male patient presented to our hospital on May 10, 21 with complaints of fever (high grade 102–103 F) with chills – 2–3 episodes per day, dry cough, severe myalgia, and generalized weakness since May 1, 21. He consulted a physician and got tested for SARS-CoV-2 which came positive on May 4, 21. Thereafter, patient was under home isolation and took conservative treatment. He then developed shortness of breath, chest heaviness, one episode of blood tinged sputum, and desaturated at home after which he was admitted to a local hospital. His oxygen saturation (SpO<sub>2</sub>) was 80 % on room air and was given loading dose of Inj. Remdesivir (200 mg), IV steroids, anticoagulants,

and O<sub>2</sub> therapy. His high-resolution computed tomography was done on May 8, 21 which showed bilateral peripheral extensive ground glass opacity with computed tomography (CT) severity score of 18/25 [Figure 1].

He continued to deteriorate and was referred to our center on May 10, 21. On admission, he was conscious, oriented, vitals: Stable, SpO<sub>2</sub>: 83 on room air and 90–95% on HC Mask (NRBM) at 15 l/min, Chest: bilateral rhonchi present, rest of the examination was within normal limits. He also complained of anosmia from May 5, 21. He was admitted in intensive care unit and given Inj Remdesivir (100 mg iv for 4 days), Inj Solumedrol (500 mg iv for 3 days followed by 60 mg iv BD), Inj Enoxaparin (60 mg/0.6 mL sc BD), Inj Tocilizumab (100 mg iv one dose), Inj Mucinac (600 mg iv TDS), Inj Meropenem (1 g iv TDS), and other supportive treatment. His SpO<sub>2</sub> dropped on high flow oxygen so patient was taken on non-invasive ventilation support (fraction of inspired oxygen [FiO<sub>2</sub>]: 100%, positive end-expiratory pressure 6 mmHg, inspiratory positive airway pressure 10 mmHg). His reports are as in [Table 1]. Patient improved clinically and chest X-ray started to show resolution of pneumonia along with decrease in FiO<sub>2</sub> demand. Patient was given high concentration mask or non rebreather mask (HCM) trial on May 18, 21, and with further improvement was shifted to ward on nasal prong at 2–3 liters/min on May 20, 2021, and discharged on oral steroids, anticoagulants, antibiotics on May 22, 2021, and he maintained SpO<sub>2</sub> of 95–96 % on room air. On discharge, patient had no neurological complaints,



**Figure 1:** (a) High-resolution computed tomography (CT) chest of patient with CT severity score of 18/25 as on day 8. (b) Arterial blood gas and chest X-ray of patient as on day 8.

**Table 1:** Sequential blood investigations.

	May 11, 2021	May 12, 2021	May 13, 2021	May 14, 2021	May 17, 2021	May 18, 2021	May 19, 2021	May 24, 2021	May 25, 2021
Hemoglobin g/dL	13.4	13.9	13.5	-	13.8	-	-	15.4	-
Leukocyte count $\times 10^9/L$	15.3	15.6	13.9	21.2	17.8	-	14.2	11.0	-
Platelet count $\times 10^9/L$	2.47	2.67	2.63	-	2.67	-	-	3.65	-
Neutrophil/lymphocyte	93/5	91/5	94/4	-	92/6	-	-	80/8	-
Lactate dehydrogenase $\mu/L$	899	-	-	500	-	-	-	-	350
Serum C-reactive protein level mg/L	18.7	11.9	5.0	-	-	-	3.1	-	0.3
Ferritin $\mu g/L$	>1000	-	-	>1000	-	-	-	359	100
Serum creatinine kinase level u/L	-	-	-	-	-	-	-	-	100
Serum troponin t ng/L	0.07	-	-	-	-	-	-	-	-
Serum Vitamin B12 ng/L	-	-	-	-	-	-	-	556	-
Serum folate $\mu g/L$	-	-	-	-	-	-	-	18	-
Serum magnesium mmol/L	-	-	-	-	-	-	-	3.0	-
Serum calcium mmol/L	8.6	9.0	-	-	-	-	-	9.5	-
Blood urea nitrogen/Serum creatinine	19/0.6	26/0.5	-	-	-	-	18/0.6	-	-
Serum sodium	139	135	-	-	-	-	135	-	139
Serum potassium	4.4	4.3	-	-	-	-	4.1	-	4.0
Serum glutamic-oxaloacetic transaminase/Serum glutamic-pyruvic transaminase	43/27	-	-	-	-	-	22/27	-	-
Serum thyroid stimulating hormone mU/L	-	-	-	-	-	-	-	-	4.36
Interleukin-6	3000	-	-	-	-	-	-	1455	-
D-Dimer	436	2804	4980	-	3620	4920	3200	2000	500
Serum procalcitonin	0.13	-	-	0.5	-	-	-	-	-

and on examination, nervous system was intact ruling out any critical illness neuropathy. The patient later presented to emergency department again on May 25, 2021 with complaint of sudden severe bilateral leg pain, numbness and weakness which gradually involved both hands. He described pain as very severe (9/10), burning stabbing and aching at times, and waxed and waned over the past 1–2 days. The pain was not relieved by paracetamol, etoricoxib, diclofenac, and injectable tramadol. He defined the pain as “pain crisis” which along with numbness affected his ambulation and daily activity. His vitals were stable. Respiratory examination revealed bilateral crepts, rest was within normal limits. His power was symmetrical 5/5 in all upper and lower extremity groups with preserved symmetrical superficial and deep tendon reflexes. Cranial Nerve examination was within normal limits except first cranial nerve wherein sense of smell was absent. He had sensory ataxia, rest of the neurological examination was normal. All routine and relevant investigations sent which were normal [Table 1]. Neurologist’s opinion was taken and NCV, EMG of all four limbs were advised. Although there was no motor involvement, still differential of Guillain-Barré Syndrome (GBS) was considered and lumbar puncture done

and was normal. EMG was normal and NCV showed Bilateral lower limb axonal sensory neuropathy [Figure 2]. Small fiber involvement was thus the causative factor for his ongoing neuropathic pain. Further Vitamin B12 was normal, Crp and ldh were elevated on earlier admission and normalised during 2nd admission ruling out Inflammatory or critical illness neuropathy and creatine kinase was normal. Diagnosis of SARS-CoV-2 associated peripheral neuropathy was considered. MRI brain and spine were also normal and patient started on pulse therapy with intravenous methyl prednisolone for 3 days, gabapentin, thiamine, and neuroprotective RITALA 354 mg (a blend of Palmitoylethanolamide (PEA), genistein, daidzein) was started on advice on neurologist along with analgesics. This was accompanied with extensive physiotherapy, high protein diet, Vitamin D and calcium supplementation, patient was given steroid pulse therapy for 3 days followed by low dose steroids and anticoagulants. He showed slow but progressive improvement in pain and ability to perform his daily activity. On day 6, he was able to walk without assistance, pain severity of 3–4/10 only in lower limbs. His chest X-ray on day of discharge showed significant resolution. He was discharged on Tab. Gabapentin 400 mg, thiamine, Cap RITALA and Apixaban.



**JAIPUR GOLDEN HOSPITAL**  
Multi Speciality Hospital  
Date: 26 MAY, 2021

NAME: \_\_\_\_\_  
AGE/SEX: 35YRS/M  
REG NO.: 1001092970  
REFERRED BY: DR. RAM BABU

**NERVE CONDUCTION STUDY OF UPPER AND LOWER LIMBS**

**MOTOR NERVE CONDUCTION**

CMAPs amplitude of both Median, both Ulnar, both Common Peroneal (CP) and both Posterior Tibial (PT) nerves are normal.

Distal Latencies and conduction velocities are normal in both upper and lower limbs.

No conduction block is seen over all nerve distribution.

F-wave latencies of B/L Median, B/L Ulnar, B/L CP and B/L PT nerves are normal.

H-Reflex is not recordable bilaterally.

**SENSORY NERVE CONDUCTION**

SNAPs amplitude and Conduction velocity are reduced B/L Sural nerve.

SNAPs amplitude of both Median and both Ulnar are normal.

Distal Latencies and Conduction velocities of both Median, both Ulnar nerves are within normal limits.

**IMPRESSION:** Nerve Conduction study of both Upper and Lower limbs shows Axonal sensory neuropathy in lower limbs.

**Figure 2:** Nerve conduction velocity test of all limbs showing axonal sensory neuropathy.

At 1-week follow-up, he showed significant improvement in the neuropathic pain. Neurologic examination was normal with normal power, tone, and sensation with significant improvement in anosmia. His repeat SARS-CoV-2 Reverse transcription polymerase chain reaction was also negative.

## DISCUSSION

Neurological manifestations in COVID may occur in both symptomatic and asymptomatic patients. Neurologic manifestations commonly described in COVID-19 patients involve the central nervous system, PNS, and skeletal muscles. Patients with a severe course of COVID-19 are more likely to develop neurological dysfunctions, among which acute cerebrovascular disease, conscious disturbance, and skeletal muscle injury are highly prevalent. Some patients manifest only neurological symptoms, including headache, languidness, malaise, cerebral hemorrhage, or cerebral infarction.<sup>[2]</sup> The SARS-CoV-2 virus enters into the central nervous system through hematogenous, lymphatic, synapse-connected, or retrograde neuronal routes.<sup>[5]</sup> Neuroinvasion of SARS-CoV-2 and the presence of neurological manifestations might be an explanation of the presence of neurological impairments.

Some studies have reported a possibility of the occurrence of the Miller Fisher syndrome (MFS), polyneuritis cranialis, or encephalopathy in COVID-19 patients.<sup>[6]</sup> Another

neurological disease commonly associated with COVID-19 is the GBS, reported as a neurological complication due to SARS-CoV-2 infection in several patients so far.<sup>[7]</sup> Detailed clinical, neurological, and electrophysiological examinations are of utmost importance to assess neurological symptoms of COVID-19 patients. In addition, the above mentioned examinations are highly important, since neurological manifestations could appear alone and might present as non-specific symptoms in patients infected by SARS-CoV-2.

In COVID-19, around one-third of patients experience different neurological symptoms, which may involve the central nervous system (dizziness, headache, impaired consciousness, acute cerebrovascular disease, ataxia, and epilepsy), the PNS (taste impairment, smell impairment, vision impairment, and neuralgia) and skeletal muscular damage. Mao *et al.* reported PNS effects in their study presenting in the form of dysgeusia (5.6%), dysosmia (5.1%), visual disturbances (1.4%), and neuralgia (2.3%).<sup>[3]</sup> Abdelnour *et al.* reported a case of peripheral neuropathy manifesting before the onset of the typical flu-like symptoms of the novel COVID-19 infection.<sup>[8]</sup>

Sheraton *et al.* hypothesized that CNS symptoms may occur due to the inflammatory mechanisms and PNS due to immune-mediated processes,<sup>[9]</sup> but more research is needed to explain SARS-CoV-2 related neuropathy. Inflammasomes are a crucial part of the inflammatory cascade. They are engaged in the production of pro-inflammatory cytokines. Microglia, astroglia, and neurons are numbered among cells expressing inflammasomes. Specific inflammatory ligands (pathogen-associated molecular patterns and damage-associated molecular patterns) participate in the activation of inflammasomes. The former ones are particles of pathogens like nucleic acid or lipopolysaccharides, the latter ones are released from distressed cells in the central nervous system.

Meanwhile, the number of reports on patients suffering from COVID-19 with neurological symptoms is growing and the role of the SARS-CoV-2 role in the neuropathogenic invasion remains unclear and needs further studies. Helms *et al.* showed that patients with COVID-19 had neurological symptoms such as perfusion abnormalities, confusion, agitation, and ischemic stroke. Like in our case Su *et al.* suggest that central pain could be induced through the angiotensin converting enzyme-2 (ACE2)-positive cells in the human spinal dorsal horn through the decrease of functional, which then results in the accumulation of Ang. II (Angiotensin II) and the decrease of (Angiotensin 1-7).<sup>[10]</sup> The pain induced by COVID-19 infection could result from the effect of spinal ACE2 on pain sensation and the direct or indirect tissue damage, but the ACE2 role in the transmission and management of pain in infected patients needs further investigation.

We reported a case of axonal sensory neuropathy in association with SARS-CoV-2 infection with near complete

resolution with immune-modulation, symptomatic therapy, and intensive rehab. As for objective findings, our patient had 5/5 strength (motor), examination with sensory ataxia (sensory), and subjective paresthesia and pain which made us conclude he had a motor neuropathy. The spectrum of neurological manifestations in association with COVID-19 continues to expand. It remains unclear which factors are associated with increased risk of neurologic manifestation. It was suggested that neurological symptoms are more common in patients with severe disease. Furthermore, several reports of patients who were admitted having apparently stable illness, yet had a happy hypoxia syndrome just like our patient. Its mechanism is not clear but a few authors suggest a possibility of autonomic neuropathy in nerves innervating respiratory system.<sup>[11]</sup>

Our differential diagnosis included acute inflammatory demyelinating polyneuropathy (i.e., AIDP or Guillain-Barre syndrome), but it is possible that subacute peripheral neuropathy may be a manifestation of a post-viral inflammatory syndrome that is distinct from AIDP. Post-viral inflammatory syndrome has peak symptoms at onset followed by progressive improvement. Furthermore, preserved deep tendon reflexes and the absence of a length dependence of symptoms argued against AIDP. Several case reports of SARS-CoV-2 develop MFS, a subtype of GBS that can manifest days to a week after an upper respiratory tract infection. Our patient lacked the characteristic MFS triad of ataxia, ophthalmoplegia, and areflexia. One study suggested the potential of a post-COVID-19 neuroimmune syndrome to include fatigue, diffuse myalgia, depressive symptoms, and disturbed sleep.<sup>[12]</sup> A diagnosis of Vitamin B6 includes manifestations such as weakness, paresthesia, confusion, and sensory or dermatologic findings as well as physical examination findings such as stomatitis, glossitis, angular cheilitis, and seborrheic dermatitis. Our patient did not have any of these findings.

There are no clinical studies on the use of gabapentin for SARS-CoV-2-related neuropathic pain, but they are traditionally used in neuropathic pain, in general. Overall treatment should be an individualized approach based on the patient's condition and pain level.

## CONCLUSION

Not many neurological manifestations of SARS-CoV-2-infected patients have been documented during this pandemic. Our case presented with pure axonal sensory neuropathy post severe COVID pneumonia. The incidence of COVID-19 has grown dramatically around the world in recent months, and most cases are asymptomatic or mild and self-managed. The association of neurological manifestations with COVID-19 is still uncertain because many cases are also misdiagnosed as other febrile illnesses.

Therefore, neurological manifestations of COVID-19 should be included in the differential diagnosis of patients with these neurological signs and symptoms. Diagnostic tests for SARS-CoV-2 should be performed in all patients with symptoms of respiratory illness and neurological symptoms.

## SUMMARY

COVID-19 has caused a havoc and one of the worst pandemics in history known to human kind. The severity of disease ranges from mild cough and cold to as severe as patients needing ventilatory supports, extracorporeal membrane oxygenation, and lung transplants to even worse outcomes like death. The primary care and family physicians played a very important role in this pandemic, but their role does not end at just treating COVID and its complications, but also the aftermath left by it. Long COVID has been talked about a lot, but this case reports a rare neurological complication in a post-COVID patient that left a young man moribund. He developed post COVID pure axonal sensory neuropathy, diagnosis of which could easily be done with clinical judgment, and investigations. Treatment was as simple, which can be administered at primary care level, leading to astonishing recovery. Hence, our case report emphasizes to broaden our view about such rare complications occurring after COVID-19 which have been reported less. Primary care and family physicians play a crucial role in identifying such cases, with diagnosis and treatment and if needed timely referral, significantly reducing mortality and morbidity due to these.

## Declaration of patient consent

The authors certify that they have obtained all appropriate patient consent.

## Financial support and sponsorship

Nil.

## Conflicts of interest

The second author Prof. R. G. Saini is a member of Editorial Board of AUJMSR.

## REFERENCES

1. World Health Organization. Statement on the Second Meeting of the International Health Regulations Emergency Committee Regarding the Outbreak of Novel Coronavirus (2019-nCoV). Geneva, Switzerland: World Health Organization; 2005. Available from: [https://www.who.int/news/item/30-01-2020-statement-on-the-second-meeting-of-the-international-health-regulations-\(2005\)-emergency-committee-regarding-the-outbreak-of-novel-coronavirus-\(2019-ncov\)](https://www.who.int/news/item/30-01-2020-statement-on-the-second-meeting-of-the-international-health-regulations-(2005)-emergency-committee-regarding-the-outbreak-of-novel-coronavirus-(2019-ncov)) [Last accessed

- on 2020 Jan 30].
- Wang HY, Li XL, Yan ZR, Sun XP, Han J, Zhang BW. Potential neurological symptoms of COVID-19. *Ther Adv Neurol Disord* 2020;13:1756286420917830.
  - Mao L, Jin H, Wang M, Hu Y, Chen S, He Q, *et al.* Neurologic manifestations of hospitalized patients with coronavirus disease 2019 in Wuhan, China. *JAMA Neurol* 2020;77:683-90.
  - Ftiha F, Shalom M, Jradeh H. Neurological symptoms due to Coronavirus disease 2019. *Neurol Int* 2020;12:8639.
  - Marc D, Dominique JF, Brison É, Desjardins J, Meessen-Pinard M, Jacomy H, *et al.* Human Coronavirus: Respiratory Pathogens Revisited as Infectious Neuroinvasive, Neurotropic, and Neurovirulent Agents. USA: CRC Press; 2013. pp. 93-122.
  - Filatov A, Sharma P, Hindi F, Espinosa PS. Neurological complications of Coronavirus disease (COVID-19): Encephalopathy. *Cureus* 2020;12:e7352.
  - Zhao H, Shen D, Zhou H, Liu J, Chen S. Guillain-Barré syndrome associated with SARS-CoV-2 infection: Causality or coincidence? *Lancet Neurol* 2020;19:383-4.
  - Abdelnour L, Abdalla ME, Babiker S. COVID 19 infection presenting as motor peripheral neuropathy. *J Formos Med Assoc* 2020;119:1119-20.
  - Sheraton M, Deo N, Kashyap R, Surani S. A review of neurological complications of COVID-19. *Cureus* 2020;12:e8192.
  - Su S, Cui H, Wang T, Shen X, Ma C. Pain: A potential new label of COVID-19. *Brain Behav Immun* 2020;87:159-60.
  - Gupta H, Nigam N, Verma SK, Gautam M. Our knowledge of Covid-19 is expanding and accelerating fast. *J Family Med Prim Care* 2020;9:5419-20.
  - Perrin R, Riste L, Hann M, Walther A, Mukherjee A, Heald A. Into the looking glass: Post-viral syndrome post COVID-19. *Med Hypotheses* 2020;144:110055.

**How to cite this article:** Bembey RA, Babu R. A rare post-COVID neurological complication: Case report of peripheral axonal sensory neuropathy. *Adesh Univ J Med Sci Res* 2023;5:34-9.